

# Sudden Death Due to Spontaneous Rupture of the Urinary Bladder following Acute Alcohol Inebriation- A Case report and Review of Literature

Bikash Sah<sup>1,\*</sup>, Shivendra Jha<sup>2</sup>, Dikshant Pokharel<sup>3</sup>

<sup>1</sup>Associate Professor, Department of Forensic Medicine and Toxicology, B. P. Koirala Institute of Health Sciences, Dharan, Nepal.

<sup>2</sup>Professor, Department of Forensic Medicine and Toxicology, B. P. Koirala Institute of Health Sciences, Dharan, Nepal.

<sup>3</sup>Consultant, Department of Forensic Medicine and Toxicology, Koshi Zonal Hospital, Biratnagar, Nepal.

## Abstract

Spontaneous rupture of the urinary bladder (SRUB) is a rare clinical condition. Prompt diagnosis is often difficult both clinically and radiologically and necessitates a high index of suspicion as the patients present with non-specific abdominal pain and may not offer a clear history. The depressant effect of alcohol further complicates the diagnosis. We report a case of a young male who was unable to seek medical support and was found dead within 12 hours of the onset of abdominal discomfort following acute alcohol intoxication. At autopsy, rupture of the urinary bladder with blood and blood clots was found in the pelvic cavity with no any corresponding external injury. Spontaneous rupture of the urinary bladder is a rare cause of death in acute alcohol intoxication. In order to further understand this rare condition, the review of related literature has been done.

**Corresponding author:** Bikash Sah, Department of Forensic Medicine and Toxicology, B. P. Koirala Institute of Health Sciences, Dharan, Nepal. Postal Code: 56700, Mobile: +9779852062255, Email: [bikash.sah@bpkihs.edu](mailto:bikash.sah@bpkihs.edu)

**Citation:** Bikash Sah, Shivendra Jha, Dikshant Pokharel (2020) Sudden Death Due to Spontaneous Rupture of the Urinary Bladder following Acute Alcohol Inebriation- A Case report and Review of Literature. International Journal of Global Health - 1(3):1-6. <https://doi.org/10.14302/issn.2693-1176.ijgh-20-3612>

**Keywords:** Death; Diuretics; Rupture; Urinary Bladder

**Received:** Oct 29, 2020 **Accepted:** Nov 23, 2020 **Published:** Nov 30, 2020

**Editor:** Qianqian song, Wake Forest School of Medicine, Wake Forest Baptist Comprehensive Cancer Center, Medical Center Boulevard, Winston-Salem, NC 27157, United States.

## Background

Spontaneous rupture of the urinary bladder (SRUB) in affiliation with acute alcohol inebriation driving to death is an uncommon finding<sup>1</sup>. In common, there are two conceivable clarifications for such rupture, including pathological bladder rupture<sup>2,3</sup> and idiopathic bladder rupture<sup>4</sup>. Spontaneous idiopathic bladder rupture is uncommon and, as the title infers, has no identifiable basic clarification. Idiopathic rupture is experienced in less than 1% of all cases<sup>5</sup>. Sometimes the idiopathic spontaneous rupture of the bladder is not even diagnosed or suspected amid the victim's life, being uncovered amid the autopsy<sup>5</sup>. Persistent spillage of urine does not permit spontaneous closure of the breach<sup>6</sup> needing urgent suturing through emergency laparotomy. Thus, SRUB could be a surgical crisis and can be quickly lethal if diagnosis and treatment are delayed, with the early intervention being crucial<sup>6,7</sup>. The condition carries soaring rates of morbidities and fatalities (47%)<sup>8</sup>, ascribed to the delay in diagnosis. A small number of case reports have been reported in the literature of spontaneous bladder rupture in association with either acute liquor inebriation or recent intake of excessive liquor in the absence of associated injury to the bladder<sup>1,9-15</sup>. This study has been done with an objective to report this rare case in order to make the treating doctor aware of this rare surgical emergency condition and also to understand the role of alcohol inebriation in the causation of such rare conditions with the help of reviewing a few available literature.

### Case Description

A 24 years old male with past history of occasional alcohol intake and no any significant medical history had an excessive alcohol intake since the morning of 24<sup>th</sup> July 2019. He was intoxicated which was evident through his falling down on the hotel's floor while walking at around 4:30 pm on the same day and sustained some superficial blunt trauma injuries over his head, face and right forearm region. He experienced abdominal pain similar to that of the acute abdomen for which no medical help was taken. On the next day at around 5 am, he succumbed to death within an hour of intake of water. At autopsy, blood and bloodstains were evident on the urethral meatus, on the medial aspect of left thigh and on undergarment (fig.1) with pale

appearing skin and oral mucosa at the external examination and approximately 2 liters of blood and blood clots in the pelvic and peritoneal cavity (fig.2) as well as ruptured urinary bladder with an intracavitary blood clot (fig.3) were seen on internal examination. A careful examination revealed no external injury over the trunk and lower limb regions.

## Methodology

The required literature were searched through google scholar and were reviewed. The literature reporting the case of SRUB followed by alcohol intake were included in the review and the literature reporting the case of SRUB with no history of alcohol intake were excluded from the review.

## Results

During the review of the literature, twelve such cases were found out of which ten cases were saved because of early diagnosis and prompt medical intervention. The findings of the reviewed literature are presented in table 1.

## Discussion

There are very few cases in the literature that portray the occurrence of SRUB due to liquor inebriation in the absence of associated traumatic bladder injury. Herein, we report a rare case of SRUB secondary to liquor inebriation, together with a review of the literatures, for a better understanding of this unusual phenomenon. This case could also have been saved if he could have gone to or have been taken to the hospital at the time he experienced the abdominal pain. Alcohol intake in this present-day world is common. Thus, along with treating doctors, the general public also need to be aware of this type of case. At the same time, different literature have further clarified different important aspects related to such cases. Uysal et al<sup>4</sup> was unable to find out the reason behind the spontaneous bladder rupture in a 78-year-old female presented with an acute abdomen. In a different case, a 26-year-old male presented with painless progressive abdominal distention; he was able to recoup fully after surgical repair of a spontaneous bladder perforation<sup>24</sup>. Parker et al. reported that bladder rupture can be associated with an experience of liquor fling<sup>25</sup>.

The spontaneous rupture of the bladder can be

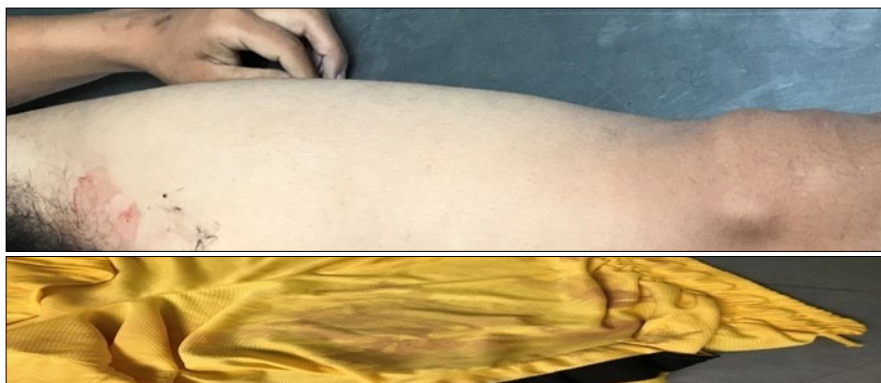


Figure 1. Blood stain on thigh and on inner garment

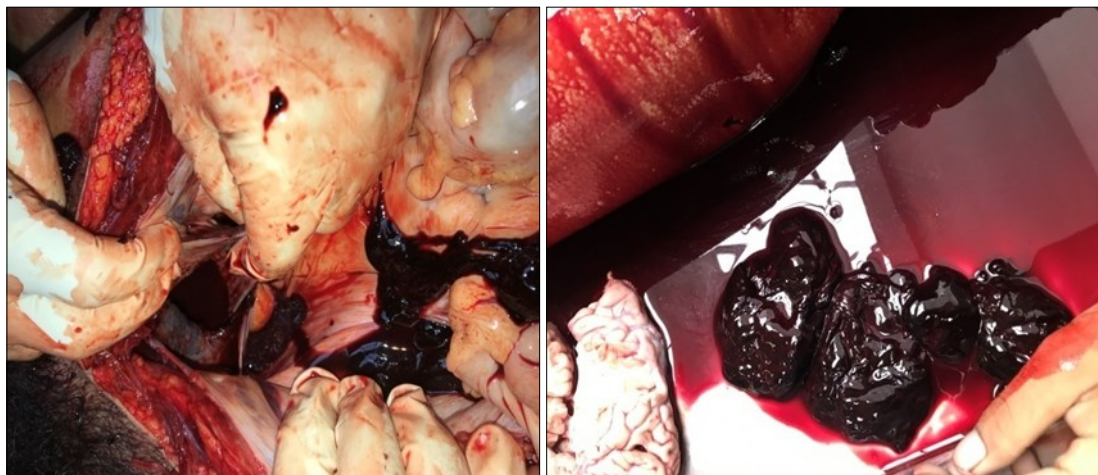


Figure 2. Blood and blood clots in the pelvic cavity

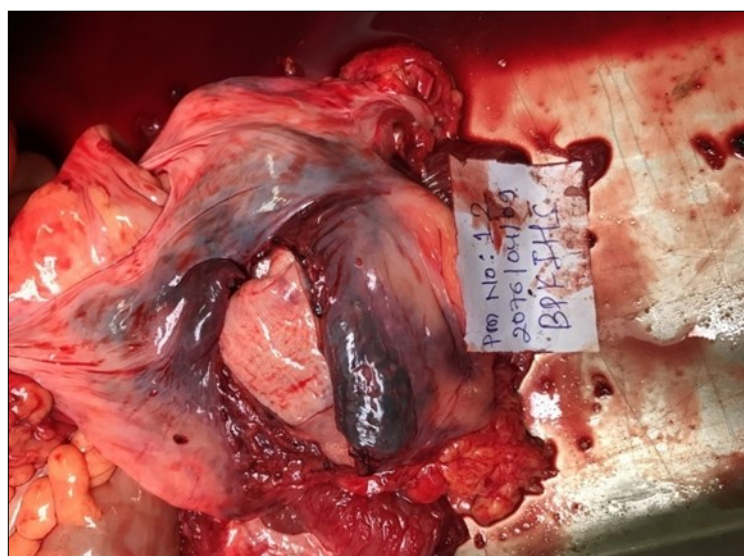


Figure 3. Ruptured Urinary Bladder

Table 1. Reported cases of SRUB with outcome

S. No.	Authors	Year	No. of cases	Outcome
1	Bennett et al <sup>16</sup>	1980	1	Survived
2	Munish et al <sup>14</sup>	1999	1	Survived
3	Dooldeniya et al <sup>17</sup>	2007	3	All survived
4	Parker et al <sup>18</sup>	2009	1	Survived
5	Dagnutt et al <sup>19</sup>	2012	1	Survived
6	Moreno-Alarcon et al <sup>20</sup>	2014	1	Survived
7	Muneer et al <sup>21</sup>	2015	1	Survived
8	Ioan B et al <sup>22</sup>	2015	1	Died
9	Zijoo et al <sup>5</sup>	2016	1	Survived
10	Nguyen et al <sup>23</sup>	2018	1	Died
11	Present case	2019	1	Died

facilitated by excessive liquor intake which has a diuretic effect<sup>1</sup> and leads to overdistension from the perspective of the sensitivity disorder due to the  $\alpha$ -sympathomimetic effect and CNS depression produced by the liquor. In a male, congestion of the prostate and prostatic urethra exaggerates the obstruction of the outlet<sup>26</sup>. However, Dooldeniya et al<sup>17</sup> reported three female cases with SRUB following liquor intake thus suggested that this type of problem should be considered among women as well. Nausea and vomiting might lead to enhanced intra-abdominal pressure and a higher probability of SRUB<sup>27</sup>. Saliba et al<sup>27</sup> suggested that patients presenting with alcohol inebriation and acute abdomen or ascites should be considered for the differential diagnoses of SRUB.

The review of the literature has clearly shown that most cases of spontaneous bladder rupture in affiliation with liquor intake are treated without complication when diagnosed quickly. Delayed diagnosis has led to considerable morbidity and fatality<sup>28</sup>. Different studies<sup>1,9,10,13</sup> have shown that SRUB following liquor inebriation is rare. Despite the infrequency, the cases in the literature retain consistency with regard to features at presentation, course, and appropriate treatment. It is important for treating doctors, especially of the emergency department to be aware of this particular condition due to the diagnostic and subsequent treatment difficulties. At the same time, the professionals in the field of forensic medicine have to

consider this entity while giving opinions about the cause of death.

### Conclusions

This case and the review of literature have shown that most of the cases of SRUB following acute alcohol intoxication can have a positive outcome with early prediction and management whereas some cases primarily discovered during autopsy due to unawareness about it among the general public as well as difficulties of its diagnosis and its rapid evolution.

### Conflict of Interest

None Declared

### Source of funding

The authors received no financial support for the research, authorship, and /or publication of this article.

### References

1. Bastable JR, Jode LD, Warren RP. Spontaneous rupture of the bladder. British journal of urology. 1959 Mar;31(1):78-86.
2. Mardani M, Shahzadi M, Rakhshani N, Rahnavardi M, Rezvani J, Sharifinejad A. Spontaneous perforation of urinary bladder secondary to Candida cystitis: acute abdomen of urologic origin. Surgical infections. 2008 Oct 1;9(5):525-7.
3. Ahmed J, Mallick IH, Ahmad SM. Rupture of urinary

- bladder: a case report and review of literature. *Cases Journal*. 2009 Dec 1;2(1):7004.
4. Uysal E, Dokur M, Ikidag MA, Kirdak T. Idiopathic spontaneous bladder perforation: a rare case. *Urology Journal*. 2015 Apr 29;12(2):2119-21.
  5. Zijoo R, Dirweesh A, Ordonez FM, Kaji A. Spontaneous Rupture of Urinary Bladder in a Young Alcoholic Male. *Journal of Medical Cases*. 2016 May 18;7(6):245-7.
  6. Jurisic D, Glavan E, Cugura JF, Vidovic D. Splenic rupture following idiopathic rupture of the urinary bladder presenting as acute abdomen. *Journal of postgraduate medicine*. 2007 Jan 1;53(1):39.
  7. Arnaout F. Spontaneous atraumatic rupture of urinary bladder. *Internet Journal of Urology*. 2008;5(2).
  8. Hansen HJ, Eldrup J. Spontaneous Rupture of the Urinary Bladder—a Late Complication to Radiotherapy: Case Report. *Scandinavian journal of urology and nephrology*. 1989 Jan 1;23(4):309-10.
  9. CORRIERE Jr JN, SANDLER CM. Management of the ruptured bladder: seven years of experience with 111 cases. *Journal of Trauma and Acute Care Surgery*. 1986 Sep 1;26(9):830-3.
  10. Christensen JB, Wara P, Hillstrøm C. Spontaneous rupture of the urine bladder: report of three cases. *Scandinavian journal of urology and nephrology*. 1986 Jan 1;20(1):73-4.
  11. Lynn SJ, Mark SD, Searle M. Idiopathic spontaneous bladder rupture in an intoxicated patient. *Clinical nephrology*. 2003 Dec;60(6):430.
  12. Marshall GA, Dixon CM, McAninch JW. Substance abuse-related spontaneous bladder rupture: report of 2 cases and review of the literature. *The Journal of urology*. 1991 Jan 1;145(1):135-7.
  13. Munshi IA, Hong JJ, Mueller CM, Barie PS. Spontaneous rupture of the urinary bladder in the alcoholic patient. *Journal of Trauma and Acute Care Surgery*. 1999 Jun 1;46(6):1133-4.
  14. Sezhian N, Rimal D, Suresh G. Isolated intraperitoneal bladder rupture following minor trauma after alcohol ingestion. *Southern medical journal*. 2005 May 1;98(5):573-5.
  15. Shumaker BP, Pontes JE, Pierce Jr JM. Idiopathic rupture of bladder. *Urology*. 1980 Jun 1;15(6):566-8.
  16. Bennett AH, Delrio A. Idiopathic rupture of the bladder: association with methamphetamine and alcohol. *The Journal of Urology*. 1980 Sep;124(3):429-30.
  17. Dooldeniya MD, Khafagy R, Mashaly H, Browning AJ, Sundaram SK, Biyani CS. Lower abdominal pain in women after binge drinking. *Bmj*. 2007 Nov 8;335(7627):992-3.
  18. Parker H, Hoonpongsimanont W, Vaca F, Lotfipour S. Spontaneous bladder rupture in association with alcoholic binge: a case report and review of the literature. *The Journal of emergency medicine*. 2009 Nov 1;37(4):386-9.
  19. Daignault MC, Saul T, Lewiss RE. Bedside ultrasound diagnosis of atraumatic bladder rupture in an alcohol-intoxicated patient: a case report. *Critical ultrasound journal*. 2012 Dec 1;4(1):9.
  20. Moreno-Alarcon C, Rigabert-Montiel M, López-Cubillana P, Gómez-Gómez G. Conservative management is a reasonable option in intraperitoneal bladder rupture. *Archivos espanoles de urologia*. 2014 Nov;67(9):788-91.
  21. Muneer M, Abdelrahman H, El-Menyar A, Zarour A, Awad A, Al-Thani H. Spontaneous atraumatic urinary bladder rupture secondary to alcohol intoxication: a case report and review of literature. *The American journal of case reports*. 2015;16:778.
  22. Ioan B, Manolescu I, Şerban DD, Neagu M, Grigoraş A, Damian S. Idiopathic spontaneous rupture of the urinary bladder-A rare cause of death. *Rom J Leg Med*. 2015 Mar 1;23(1):9-13.
  23. Nguyen T, Prahlow JA. Idiopathic bladder rupture. *Forensic Science, Medicine and Pathology*. 2018 Dec 1;14(4):548-50.
  24. Dubey IB, Mohanty D, Jain BK. Diverse presentation of spontaneous rupture of urinary bladder: review of two cases and literature. *The American journal of emergency medicine*. 2012 Jun 1;30(5):832-e1.
  25. Parker H, Hoonpongsimanont W, Vaca F, Lotfipour S. Spontaneous bladder rupture in association with

- alcoholic binge: a case report and review of the literature. *The Journal of emergency medicine*. 2009 Nov 1;37(4):386-9.
26. Kim HJ, Moon H, Sohng I, Lee HW, Lee G, Lee JG. Effects of ethanol and its metabolite acetaldehyde on responses of the rat bladder. *BJU international*. 1999;83:686-92.
27. Saliba W, Grant ME. Conservative management of spontaneous bladder rupture. *Kansas Journal of Medicine*. 2011 May 31;4(2):44-6.
28. Herd AM, Crofts NG, Lee LM, Girard JV, Sweetland RJ. Isolated bladder rupture after minor trauma in a patient with alcohol intoxication. *The Journal of emergency medicine*. 1994 May 1;12(3):409-11.